

Editor:  
Förderkreis der Esogetischen  
Medizin nach Peter Mandel e. V.

Interessengemeinschaft der  
diplomierten Therapeutinnen  
and Therapeuten der  
Esogetischen Medizin/  
Farbpunktur nach Peter Mandel

IAEC – International Association  
of Esogetic Colorpuncture

in collaboration with  
ESOGETICS GmbH

# ESOGETIC LETTERS

December 2024

Esogetic Diagnostics



**Förderkreis**  
*der Esogetischen Medizin*

*nach Peter Mandel e.V.*

The greatest care has been taken in the composition of this document with regard to the accuracy of the information contained herein.

Many of our therapeutic procedures and their effects are based exclusively on the empirical knowledge of naturopathy. Medical diagnoses and courses of treatment, especially treatment methods and their effects, are highly individual and different. For this reason, a successful treatment cannot be foreseen or guaranteed. As a precautionary measure, we therefore point out that we make this clear in the content we present with the help of the subjunctive. The word "may" therefore indicates, in the sense of an assumption or presumption, a mere possibility, the existence of which is uncertain and can be described as "perhaps" or "possibly". We therefore point out that, with regard to a possible success of treatment and the suitability of a therapy, these terms should not be understood in the sense of a promise of healing.

Please always keep in mind that certain diseases and strains are less or not suitable for self-treatment. We would like to expressly point out that before self-treatment with our products, especially in the home environment, it is advisable to consult your doctor or alternative practitioner. The author and publisher of this brochure are in no way liable for damages or consequences arising from the use of this brochure.

**Förderkreis der Esogetischen Medizin  
nach Peter Mandel e.V.**

Hildastraße 8  
76646 Bruchsal  
Tel. 07251-800135

**ESOGETICS GmbH**

Hildastraße 8  
76646 Bruchsal  
Tel. 07251-8001-0  
info-de@esogetics.com  
www.esogetics.com

**Peter Mandel Stiftung  
für Esogetische Medizin**

Hirschmattstrasse 16  
6003 Luzern  
Tel. 041-420 58 36  
www.peter-mandel-stiftung.ch

**ESOGETICS GmbH – Niederlassung**

Hirschmattstrasse 16  
6003 Luzern  
Tel. 041-420 58 36  
info-ch@esogetics.com  
www.esogetics.com

**All materials, contributions and illustrations are protected by copyright. Use and reprint – even excerpts – require written permission. © Copyright by Peter Mandel + Internationales Mandel-Institut für Esogetische Medizin**

Dear Friends of Esogetic Medicine,

in this Esogetic Letter I would like to once again use a case history to point out to you the possibilities of Esogetic diagnostics and the resulting therapies.

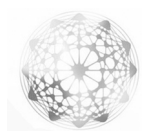In 2022 a young woman with serious problems came to my office. She complained of recurring abdominal pain, which had been so bad that twice she had to go to the hospital. There she was examined according to the present standards, and there was no discernible cause for her pain and discomfort. All exams were without findings. So the patient was classified as hysterical and referred to a psychologist. But the therapy sessions were also unsuccessful.

The patient was born in 1981, so she is still a young woman with a loving husband and two small children.

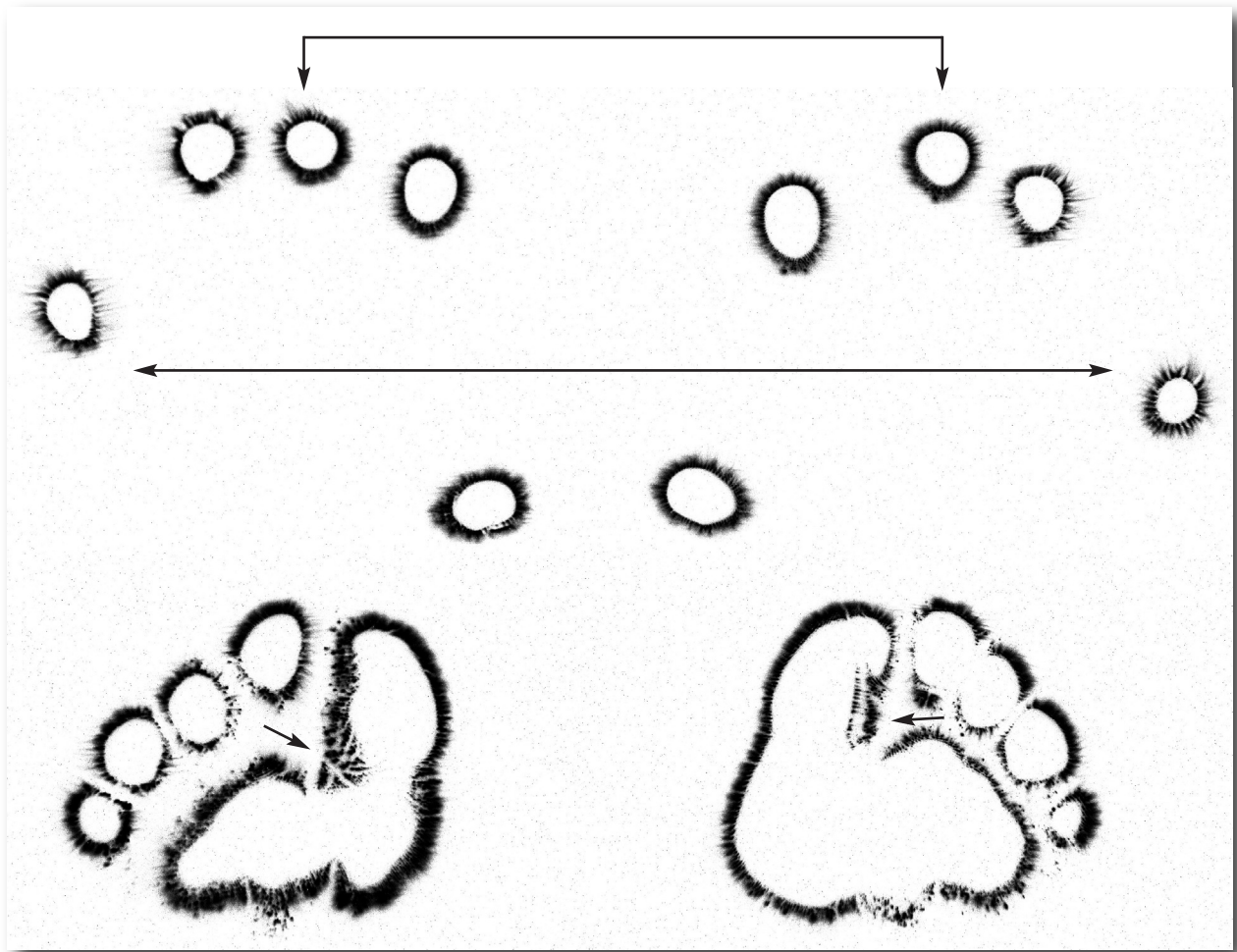
The conversations with her were quite interesting. She stated that her complaints were always particularly severe, when she got upset, which had been particularly frequent recently. Then her stomach is cramping, especially on the upper right and along the whole left side of her intestine. When I asked her, why she gets upset and thus is doing harm to herself, she said that she didn't know. "It just comes over me."

In the anamnesis she states that she had been hospitalized by herself at the age of 5. At that time she had already been suffering from abdominal complaints accompanied by persistent diarrhea. After a short time she had been discharged free of symptoms, but still remembers today how it felt to be there alone.

I would like to start with an EEA image from Dec. 14, 2022



### EEA IMAGE FROM 2022/12/14



The first EEA image shows a balanced constitution in the finger emissions. Furthermore, a slight phenomenological laterality of the middle finger on the left. This points to the time around age 6 and lets me conclude that the time, when she was in hospital as a child, probably still has a blocking effect. The little finger on the right is in laterality to the left. Here the symbol of Pluto seems to be blocking her progress from deep in the subconscious..

Important, however, are the phenomena of both big toes, especially on the left. On the lateral side on the left are the bile ducts, especially the common bile duct. On the right side at this same point we find the connection to the liver.

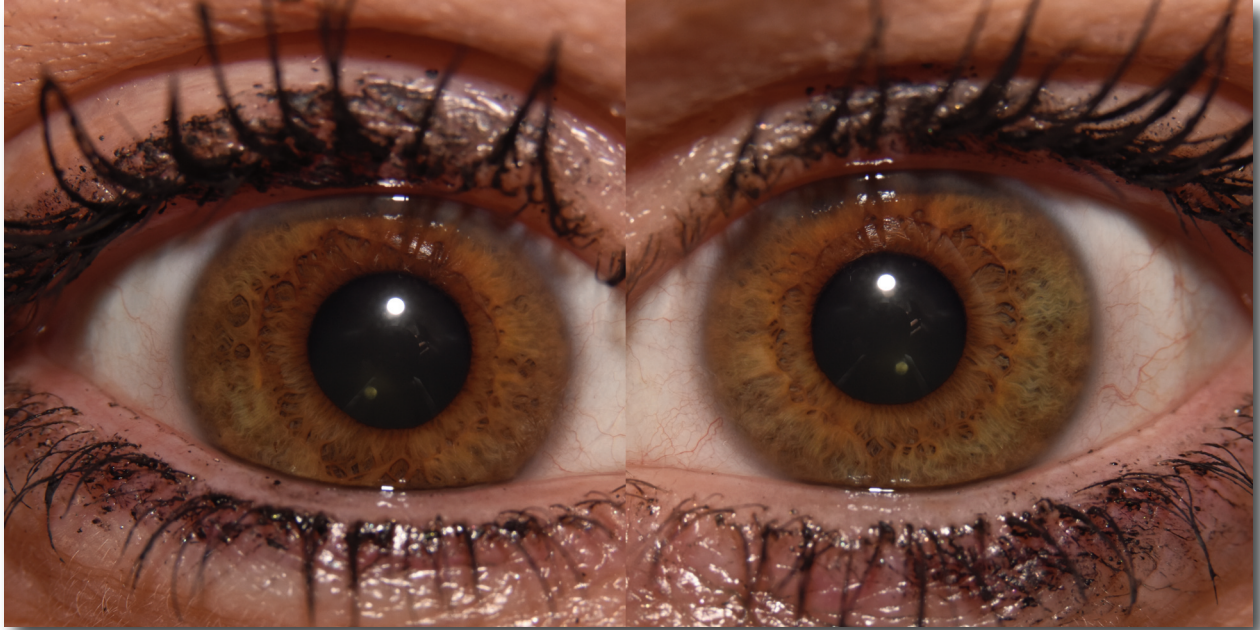
With such a phenomenology, we should always think of constellations that indicate, why the same causes (here emotion-aggression) repeatedly produce the same complaints.

For me, it is important to have a look at the genetic weaknesses that we can easily recognize through our eyes.





## THE PATIENT'S EYES



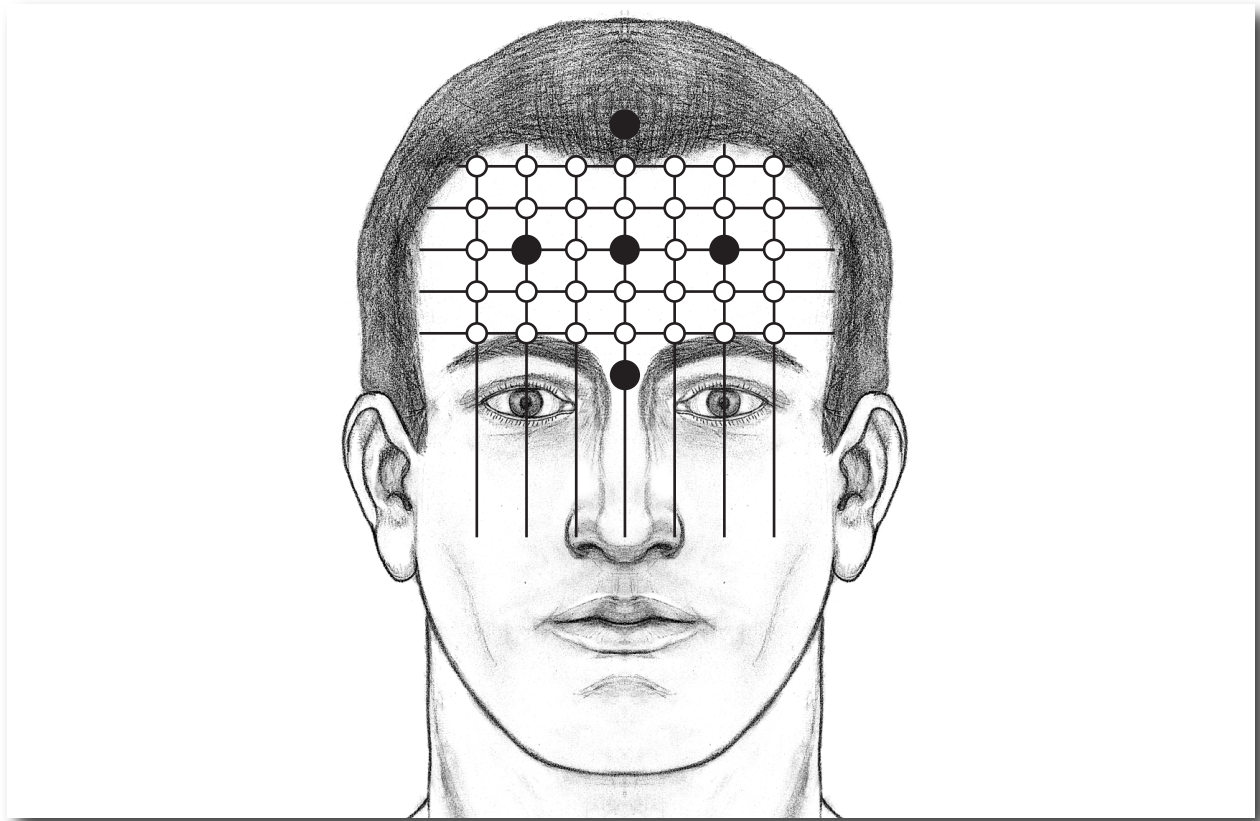
Biliary constitution. There is a burden within the intestinal ruffle with dark pigment and small lacunae. However, the field in the right iris, where the ruffle is straightened is striking. The pylorus and especially the head of the pancreas are located here, where a lighter colored patch can also be seen. We must pay attention to such signs that are already genetically inherited as weaknesses and now come into particular focus through activation (lighter sign).

Inspection of the abdomen revealed a slight swelling in her right upper abdomen, and particularly severe pain, when touching the pancreas point in the left abdomen.

I began treating the patient via the soul cross of the prefrontal cortex (PFC), the Vogler point at the right costal arch and the pancreas point on the left.



## THE SOUL CROSS OF THE PREFRONTAL CORTEX (PFC)



### Location and Treatment Sequence of the Soul Cross PFC:

The vertical points are located in the center of the forehead, 1 FW behind the hairline (birth point) and on the bridge of the nose. The horizontal points are located on the endoderm line.

#### Step 1

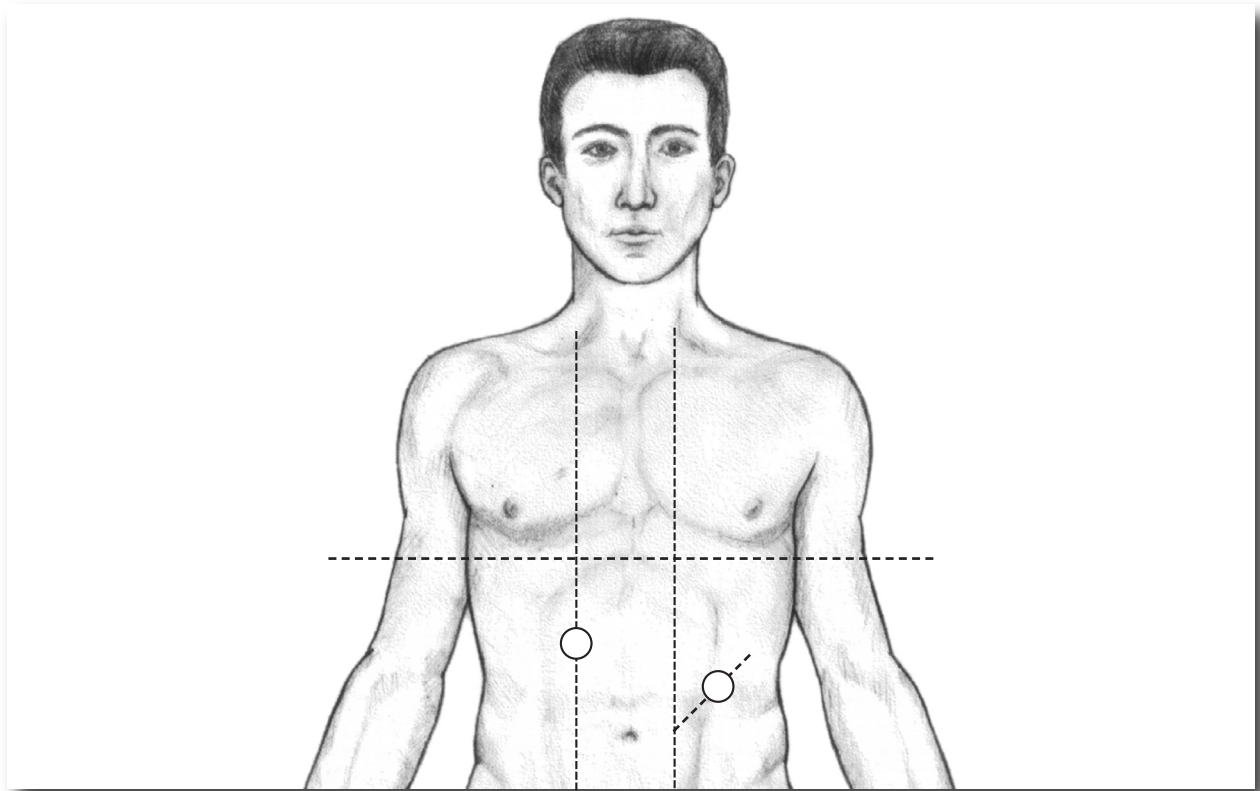
1. Acupuncture/piezoelectric impulses together with the Vogler point and pancreas point
2. Center of the forehead .....Gamma/UV
3. Gray radiation of the three vertical points
  1. Center .....Dark Gray
  2. Birth point, 1 FW behind the hairline .....Medium Gray
  3. Point on the bridge of the nose .....Light Gray

#### Step 2

4. Further treatment with the rhythms and Colorpuncture
  1. 1st birth point .....Beta/Crimson
  2. Bridge of the nose .....Delta /Lightgreen
  3. Point on the right endoderm line .....Alpha/Turquoise
  4. Point on the left endoderm line .....Theta/Rose



## VOGLER POINT AND PANCREAS POINT



### Location and Treatment Sequence of the Vogler Point and the Pancreas Point:

The Vogler point is located three fingerwidths from the tip of the sternum below the costal arch and the Esogetic pancreas point corresponds to the midpoint of a line from 2 FW next to the navel to LR 13 on the left.

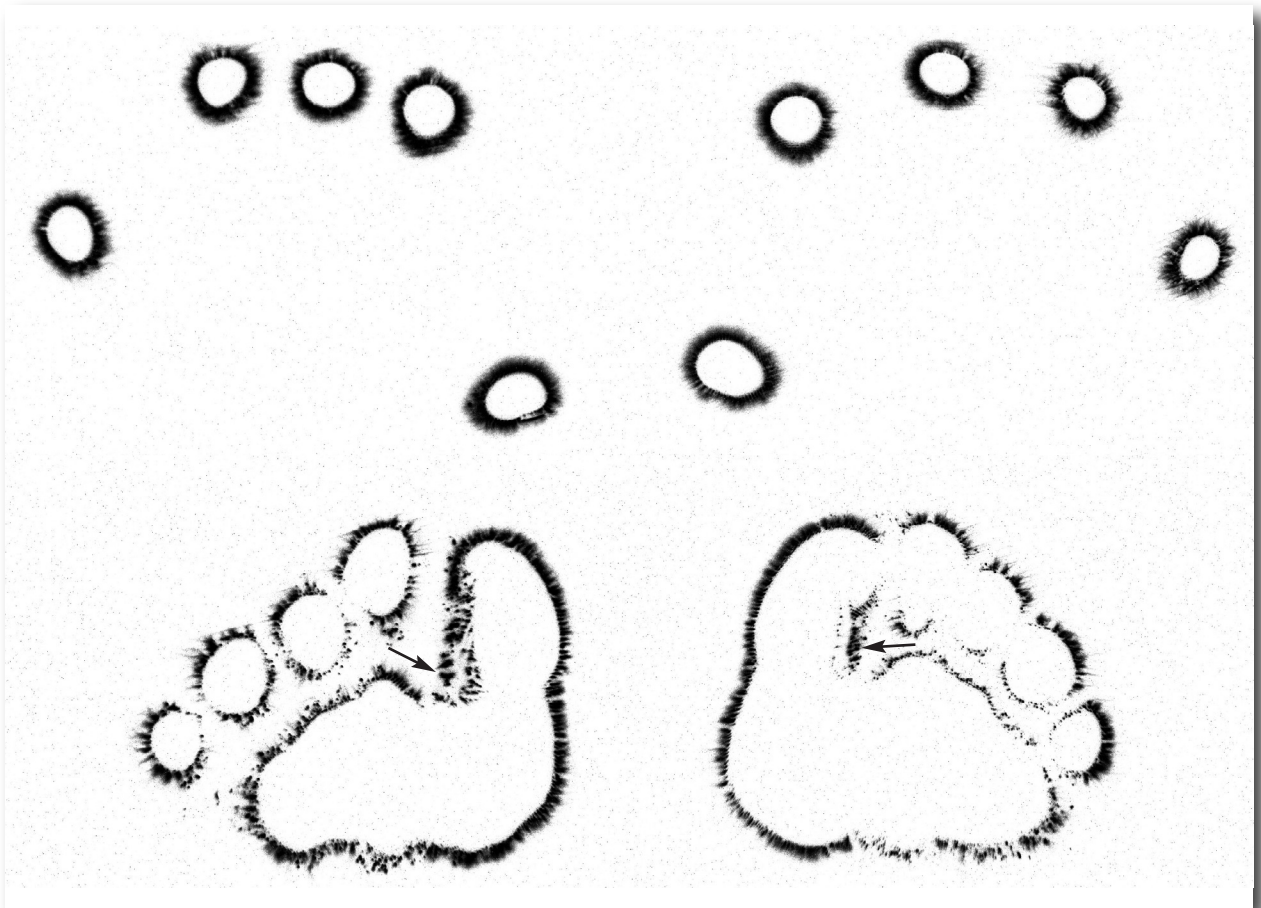
1. Acupuncture/piezoelectric impulses of the Vogler point and pancreas point
2. Colorpuncture
  1. Vogler point .....Lightgreen
  2. Pancreas point .....Crimson

or injection

3. Vogler point .....Infi-Condurango, Infirmarius
4. Pancreas point .....Digesto, Hevert

After the treatment, the patient was pain-free, and I could now also feel the pancreas point in the left upper abdomen quite well.



**EEA IMAGE FROM 2922/12/14 – CONTROL PICTURE**

There is little change in the phenomenology of the two big toes, although the previously palpated strains have been reduced. In the area of the hands, I had the impression that the phenomenological laterality had balanced.

We treated the patient at 3-week intervals and she remained pain-free for a long time. She also stated that she felt more relaxed and that the upsets she had previously experienced on a daily basis, now were only occurring occasionally. I also attributed this to her self-treatment at home.

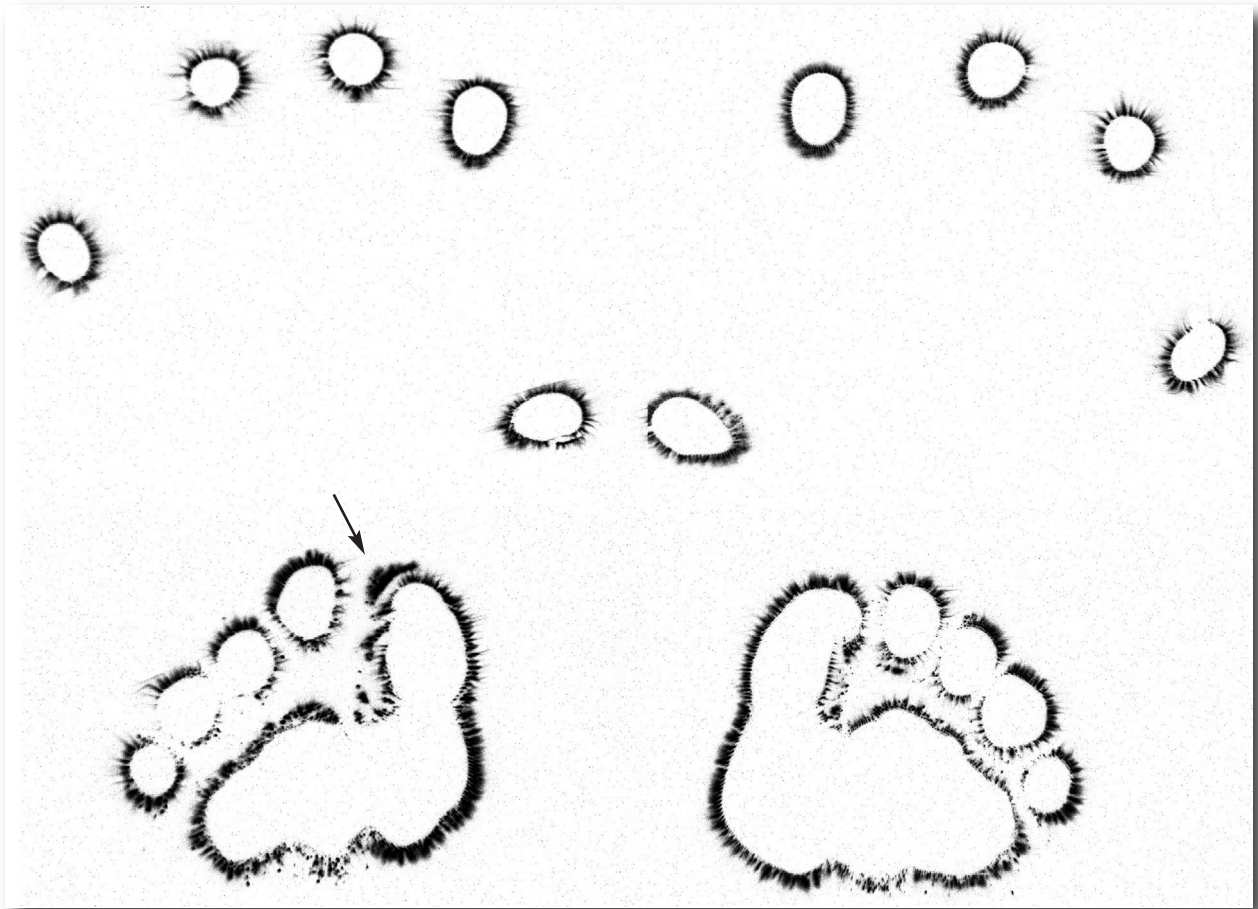
She did the Soul Cross PFC and in the evening before going to sleep she rubbed 2-3 drops of Esogetic Wild Herbal Oil relax into the Vogler and pancreas points.

After some strong turmoil in her family, at the beginning of 2025, she again experienced considerable pain in her entire abdomen. The Soul Cross, which she treated immediately, brought little relief.

I saw her again at the office on January 9, 2025.





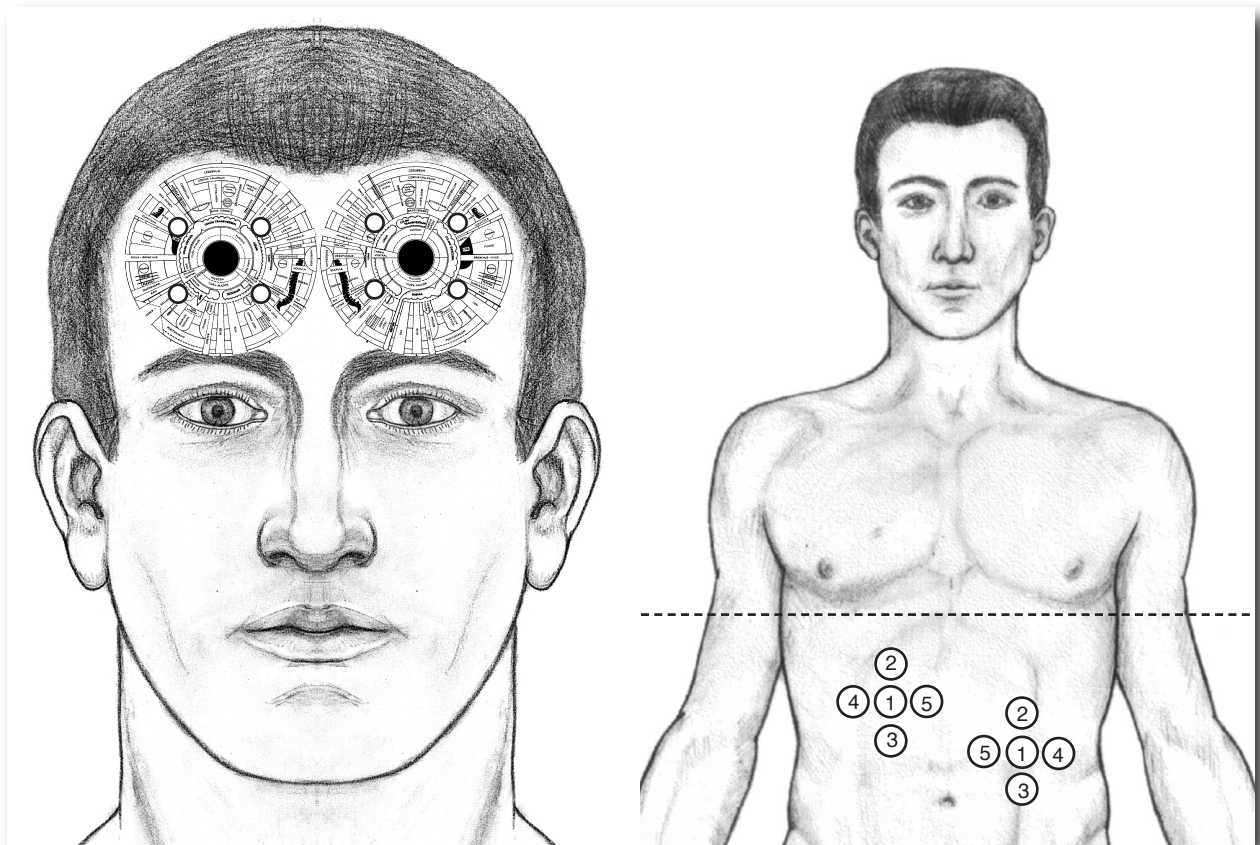
**EEA IMAGE FROM 2025/01/09**

The separation phenomenon that we can recognize at the tip of the big toe shows a connection to the spleen and thus clearly to the function circle spleen-pancreas.

Palpation of the pancreas point was very painful, as was the pancreas segment at the left shoulder. The right upper abdomen was free.

So I treated the Pancreas Cross together with the Vogler Cross and combined it with the square of the pancreas points in the OGT fields.





**Location and Treatment Sequence:**

OGT square of the pancreas (see appendix for template)

The Vogler point lies three fingerwidths from the tip of the sternum below the costal arch and the Esogetic pancreas point corresponds to the midpoint of a line from two FW next to the navel to LR 13 on the left. The points of the cross are each 1 FW away from the center.

1. Acupuncture/piezoelectric impulses of the OGT, together with the Vogler cross and the pancreas cross
2. Colorpuncture OGT  
All points .....Green
3. Colorpuncture Vogler and pancreas crosses  
Soul-Spirit-Colors
  1. Points 1/2/3 (Vogler cross) .....Crimson
  2. Points 1/4/5 (Vogler cross) .....Lightgreen
  3. Points 1/2/3 (Pancreas cross) .....Crimson
  4. Points 1/4/ (Pancreas cross) .....Lightgreen

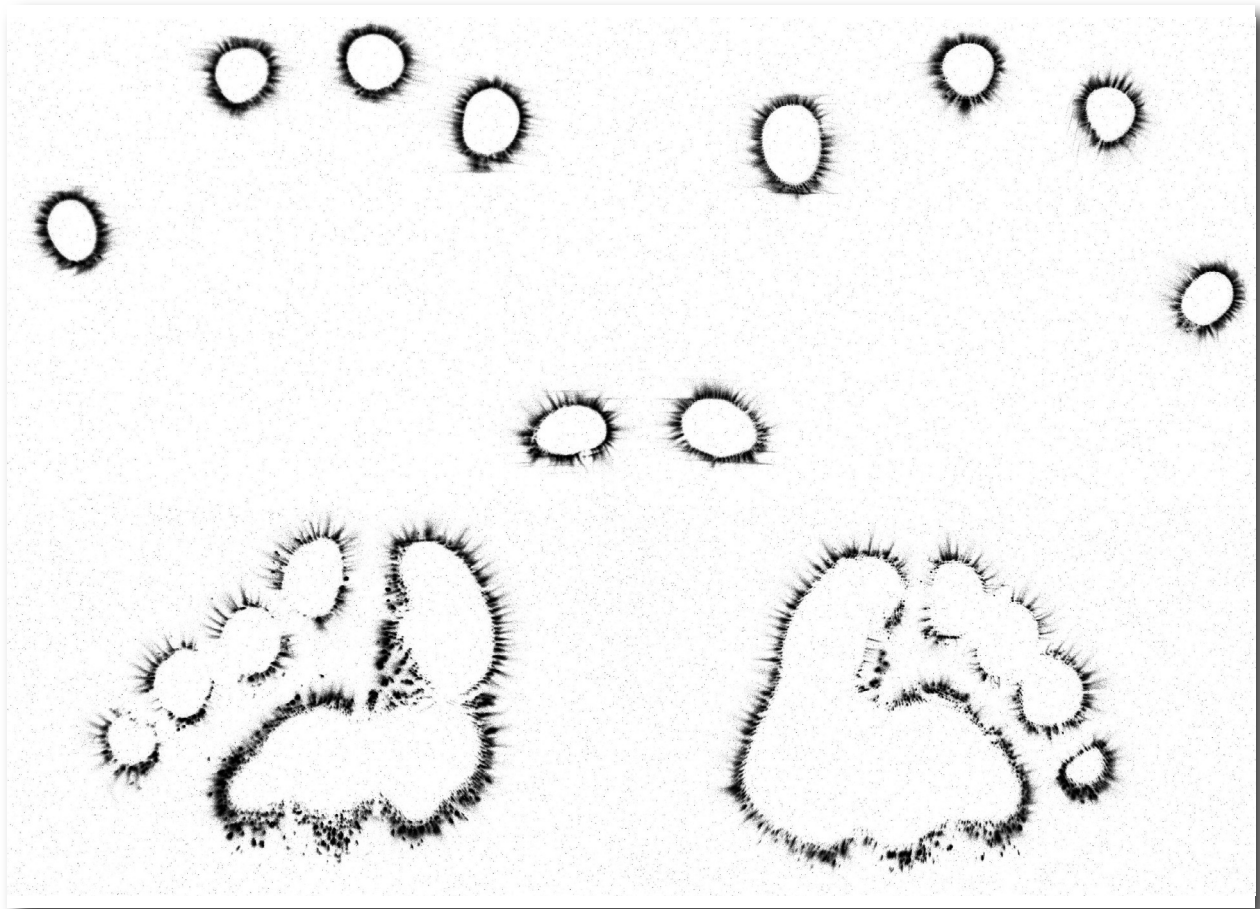
or injection

1. Vogler cross .....Infi-Condurango, Fa. Infirmarius
2. Pancreas cross .....Digesto, Fa. Hevert

Below is the control image.





**EEA IMAGE 2 FROM 2025/01/09 – CONTROL PICTURE**

The separation phenomenon has dissolved, but the area remains a focal point. It reminds us that in the future it will still be crucial, whether the patient can "come into her own". Apparently this is possible for the young woman, because I can also see that the radiation of the little finger on the right (Pluto) is opening up. Amygdala phenomena are now also recognizable in the hands. The wedge shapes of the fingers on both sides indicate this.

The liver and gallbladder, and above all the pancreas, are her weaknesses, as previously shown discussing the irises, and she will have to deal with them for the rest of her life. However, the eyes only show the dominant weakness that people always suffer, when they are unable to understand and live with their predispositions.

The solution can therefore only be that she learns to understand that the stress from childhood can have a lifelong effect. The treatments that we are carrying out are strengthening the organs, assisting her genetically determined conditions.

The patient assures us that she has understood the content of our multiple conversations, and that she will continue to try to break her addiction to the premise of "I'm always right".

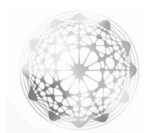

We will continue to accompany her therapeutically, because of the phenomenology that is still remaining.

See you next time

Cordially

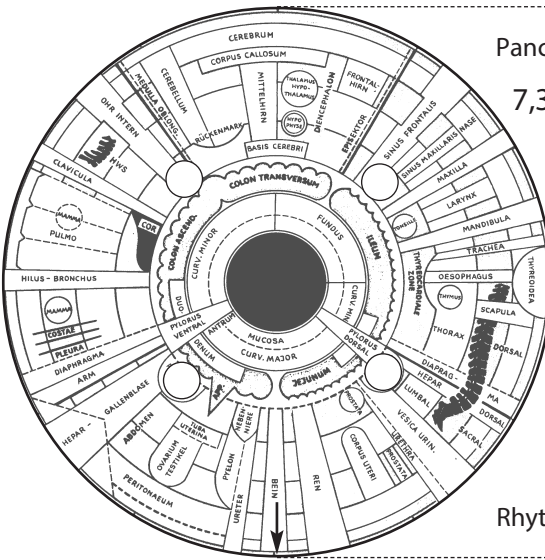
*Peter Mandel*



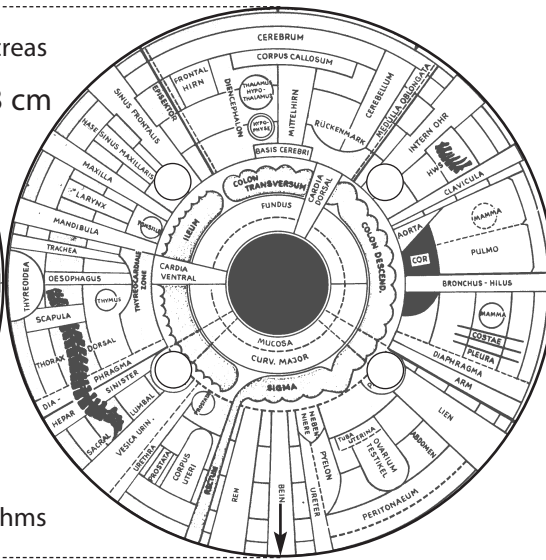
# APPENDIX

## THERAPY TEMPLATE

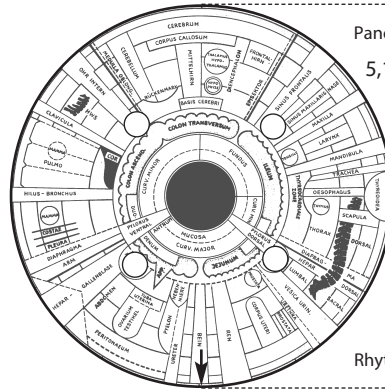




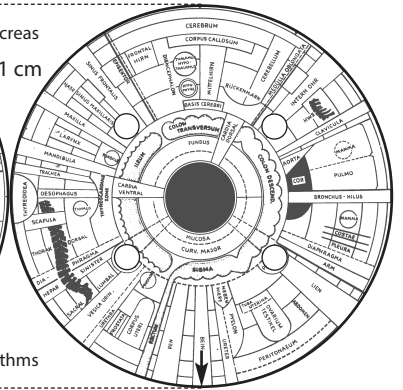
Pancreas  
7,3 cm



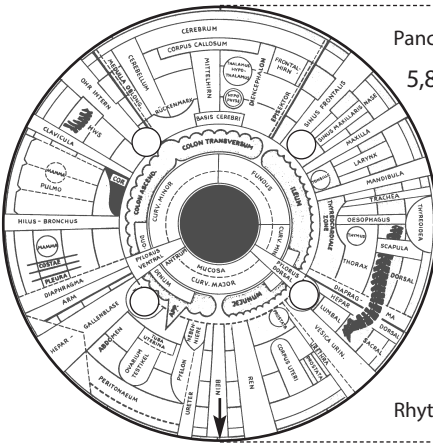
Rhythms



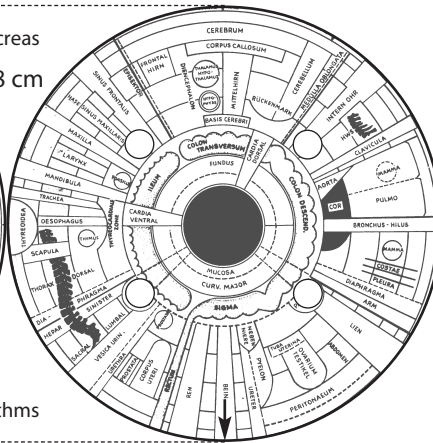
Pancreas  
5,1 cm



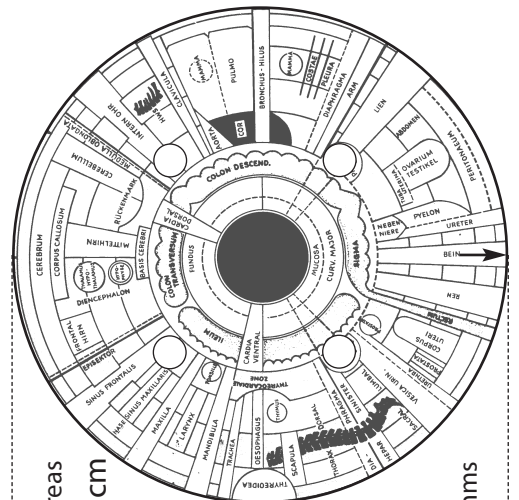
Rhythms



Pancreas  
5,8 cm

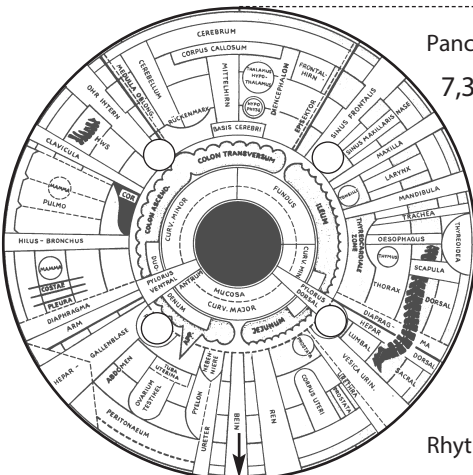


Rhythms

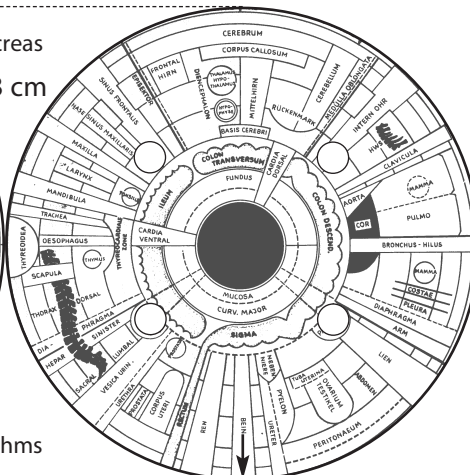


Pancreas  
7,3 cm

Rhythms



Pancreas  
7,3 cm



Rhythms

